



PATIENT

Button Lewars

SPECIES

Feline

BREED

DSH

SEX

FS

AGE

4 y

WEIGHT

11.8 lb

PRESENTING CLINICAL SIGNS

Grade 2/6 murmur. Pre-anesthetic evaluation (dental). ECG showed a single VPC.

ECHOCARDIOGRAPHIC FINDINGS

2D, M-mode, and Doppler study.

Left atrial size is normal. The mitral valve appears normal. Left ventricular wall thickness is normal. Left ventricular internal dimensions are normal. Left ventricular systolic function is hyperdynamic. The aorta and aortic valve appear normal. Right atrial and right ventricular dimensions are normal. The tricuspid valve appears normal, though trace tricuspid regurgitation is present. The pulmonary artery and pulmonic valve appear normal, though trace pulmonic insufficiency is present. No pericardial effusion or cardiac masses are seen.

LA/Ao – 1.37

IVSd – 5.4 mm

LVPWd – 4.6 mm

LVIDd – 13.6 mm

LVIDs – 4.6 mm

FS – 66%

RA – 11.2 mm

RVOT – 0.73 m/s

INTERPRETED BY

Keith Blass, DVM, MS,
DACVIM (Cardiology)

IMAGING PERFORMED BY

Tiffany Brady, DVM

HOSPITAL NAME

Shiloh VH

REFERRING VET

Dr. Herr

INVOICE

DATE

12/26/25

ASSESSMENT/RECOMMENDATIONS

This examination demonstrates no obvious evidence of structural heart disease. While a definitive reason for Button's murmur was not identified, it's likely that her murmur is functional/innocent in nature, as no flow abnormalities that could result in the development of a pathologic murmur were appreciated in the image set.

There is no contraindication to general anesthesia based on this exam, however, given that a VPC was seen in Button's ECG, I recommend avoiding the use of ketamine, telazol, and, if possible, anticholinergics in the anesthetic protocol. Careful monitoring of Button's heart rhythm is recommended during the procedure.

No therapy is recommended based on this exam.

A recheck ECG is recommended in 3 months. A recheck echocardiogram is recommended if the characteristics of Button's murmur change, or if other new physical exam and/or clinical abnormalities suggestive of cardiac dysfunction develop.



PATIENT

Button Lewars

SPECIES

Feline

BREED

DSH

SEX

FS

AGE

4 y

WEIGHT

11.8 lb

INTERPRETED BY

Keith Blass, DVM, MS,
DACVIM (Cardiology)

IMAGING PERFORMED BY

Tiffany Brady, DVM

HOSPITAL NAME

Shiloh VH

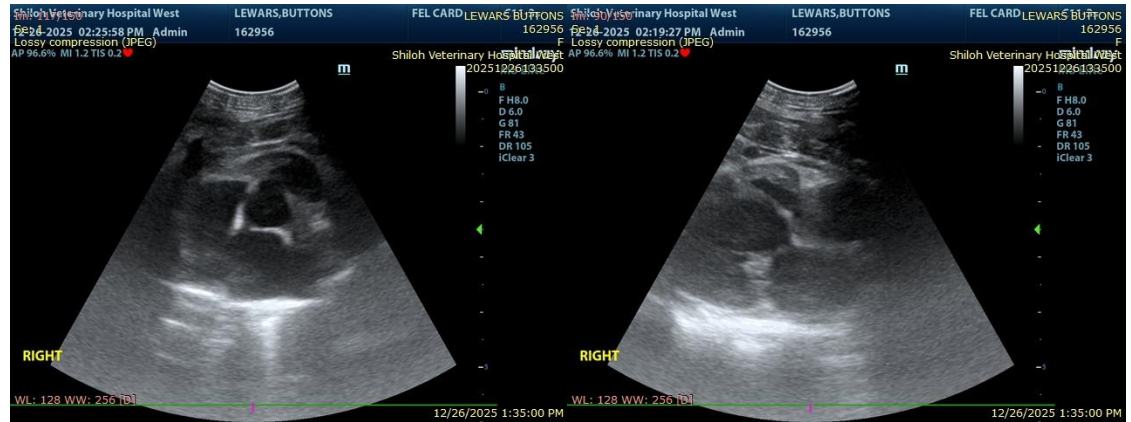
REFERRING VET

Dr. Herr

INVOICE

DATE

12/26/25



The information and recommendations provided are based on the images presented by the referring veterinarian/sonographer. No evaluation can be communicated regarding pathology that was not visible in the image/video clips provided.

Thank you for this referral. If the clinical or image interpretation does not parallel your findings or if I can be of any further assistance please contact me.

Keith Blass, DVM, MS, DACVIM (Cardiology)

info@SonoPath.com